



PATIENT PRESENTING CLINICAL SIGNS

Fritzi Mitchko Hydroureter and hydronephrosis

SPECIES

Canine

COMPUTED TOMOGRAPHIC STUDY OF THE ABDOMEN

Plain and post contrast studies are available for review.

BREED

Miniature Schnauzer

COMPUTED TOMOGRAPHIC FINDINGS

Severe pyelectasia of the left kidney is seen. Moderate hydroureter with rupture of the left ureteral wall ~ 35 mm distal to the renal pelvis is noted. Extensive retroperitoneal and peritoneal leakage of urine is noted.

A moderate amount of free peritoneal fluid is seen.

SEX

MN

Emerging left perirenal pseudocyst formation is noted and there is mild generalized distortion of the left renal architecture.

AGE

5yr

The distal left ureter contains a 4 mm x 1 mm sized calculus ~ 20 mm cranial to the ureteral papilla likely responsible for obstruction and ureteral rupture. Small calculi are noted within the renal diverticula of both kidneys.

No evidence of pyelectasia or hydroureter is seen on the right hand side.

INTERPRETED BY

Nele Eley (Ondreka),
DVM Dr. med. vet.,
DipECVDI

The pyelogram of both kidneys appears to be delayed supporting the presence of delayed renal excretion.

The urinary bladder is mildly distended. A 5 mm x 1 mm sized calculus and fine mineral attenuating sediment (sand) is seen within the urinary bladder lumen.

COMPUTED TOMOGRAPHIC DIAGNOSIS

HOSPITAL NAME

Rockaway Animal
Hospital

- Left ureteral rupture secondary to obstructing distal ureterolith.
- Severe left pyelectasia and moderate hydroureter with emerging left perirenal pseudocyst formation secondary to the urine leakage.
- Small calculi in both kidneys and mild bladder sediment.
- Urinary leakage into retroperitoneal and peritoneal spaces, as well as into the inguinal soft tissue
- Moderate free fluid and presumed peritonitis.

REFERRING VET

Dr Maniar

INVOICE

23789

INTERPRETATION OF FINDINGS & FURTHER RECOMMENDATIONS

Urgent urologic consultation for surgical management is recommended. The success of interventional management may be impaired by the presence of ureteral rupture and extensive inflammatory changes throughout the retroperitoneal and peritoneal cavity compartments.

DATE

02/04/2026

Left nephrectomy may be discussed vs left ureteral repair or stenting with removal of the ureterolith. Follow-up imaging may be considered post-intervention to assess the resolution of



PATIENT pseudocyst and urine leakage.

Fritzi Mitchko

SPECIES

Canine

BREED

Miniature Schnauzer

SEX

MN

AGE

5yr

INTERPRETED BY

Nele Eley (Ondreka),
DVM Dr. med. vet.,
DipECVDI

HOSPITAL NAME

Rockaway Animal
Hospital

REFERRING VET

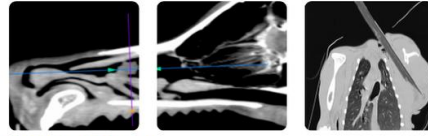
Dr Maniar

INVOICE

23789

DATE

02/04/2026



PATIENT

Fritzi Mitchko

SPECIES

Canine

BREED

Miniature Schnauzer

SEX

MN

AGE

5yr

INTERPRETED BY

Nele Eley (Ondreka),
DVM Dr. med. vet.,
DipECVDI

HOSPITAL NAME

Rockaway Animal
Hospital

REFERRING VET

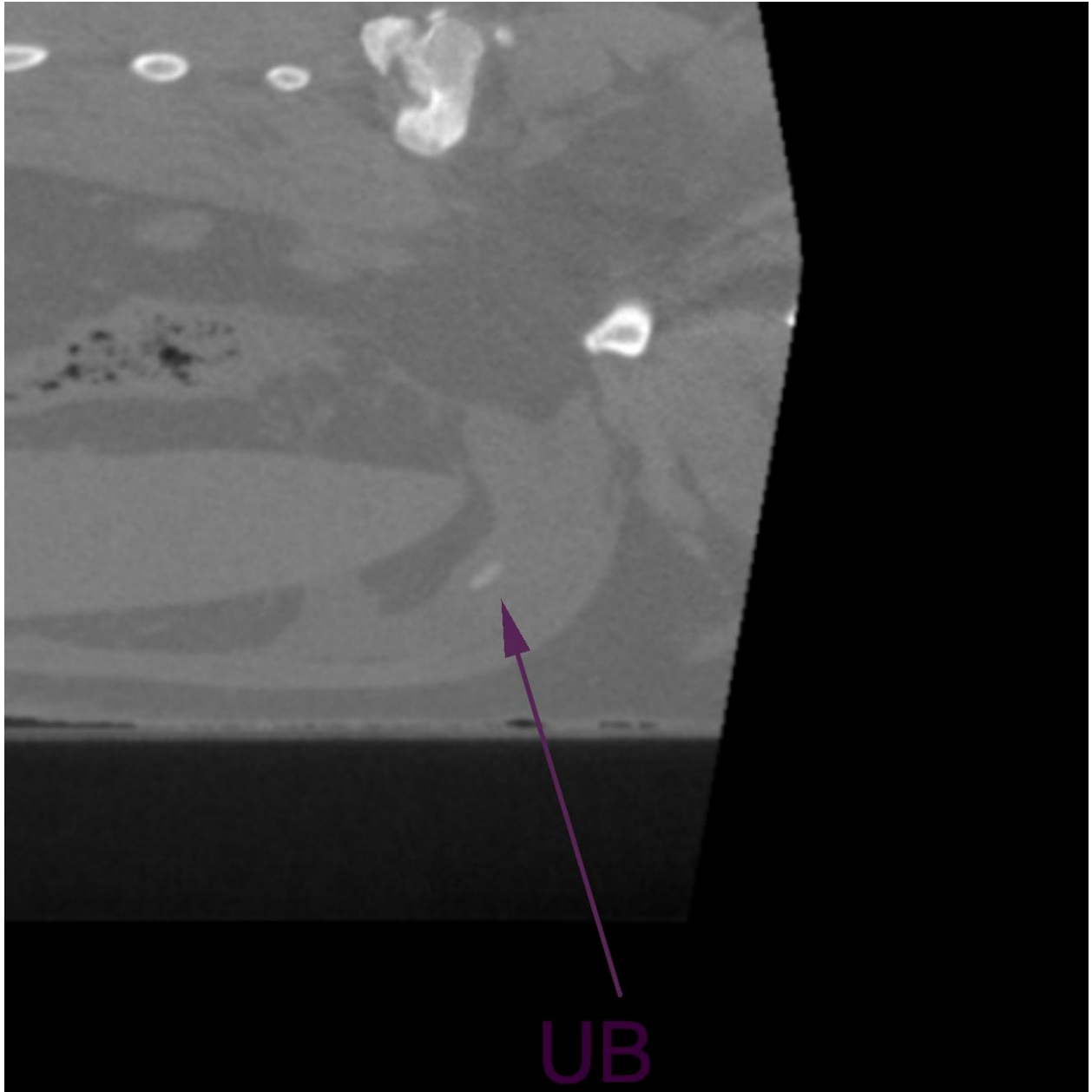
Dr Maniar

INVOICE

23789

DATE

02/04/2026





PATIENT

Fritzi Mitchko

SPECIES

Canine

BREED

Miniature Schnauzer

SEX

MN

AGE

5yr

INTERPRETED BY

Nele Eley (Ondreka),
DVM Dr. med. vet.,
DipECVDI

HOSPITAL NAME

Rockaway Animal
Hospital

REFERRING VET

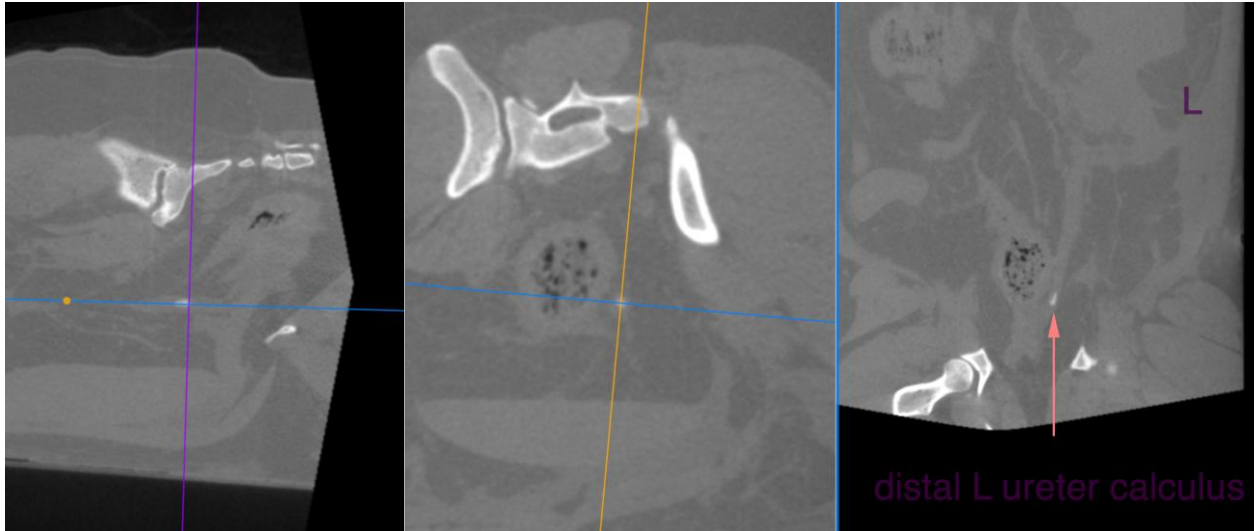
Dr Maniar

INVOICE

23789

DATE

02/04/2026





PATIENT

Fritzi Mitchko

SPECIES

Canine

BREED

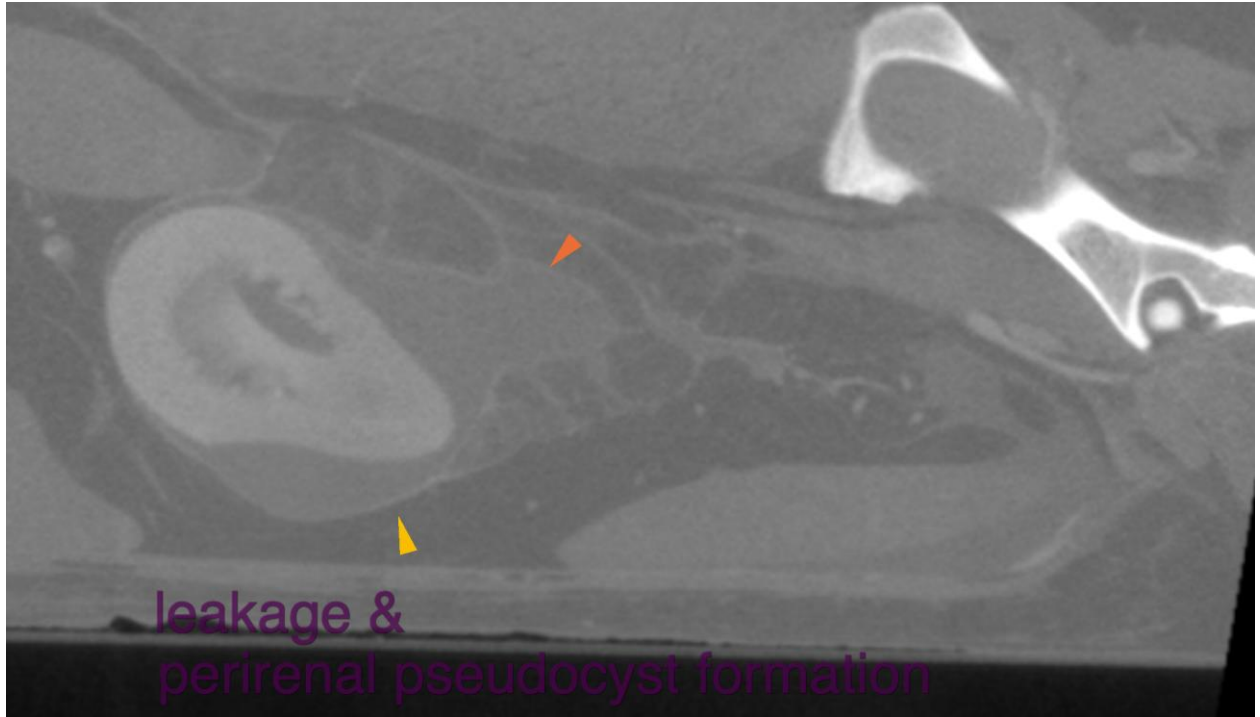
Miniature Schnauzer

SEX

MN

AGE

5yr



INTERPRETED BY

Nele Eley (Ondreka),
DVM Dr. med. vet.,
DipECVDI

HOSPITAL NAME

Rockaway Animal
Hospital

REFERRING VET

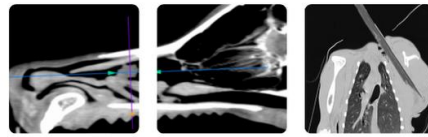
Dr Maniar

INVOICE

23789

DATE

02/04/2026



PATIENT

Fritzi Mitchko

SPECIES

Canine

BREED

Miniature Schnauzer

SEX

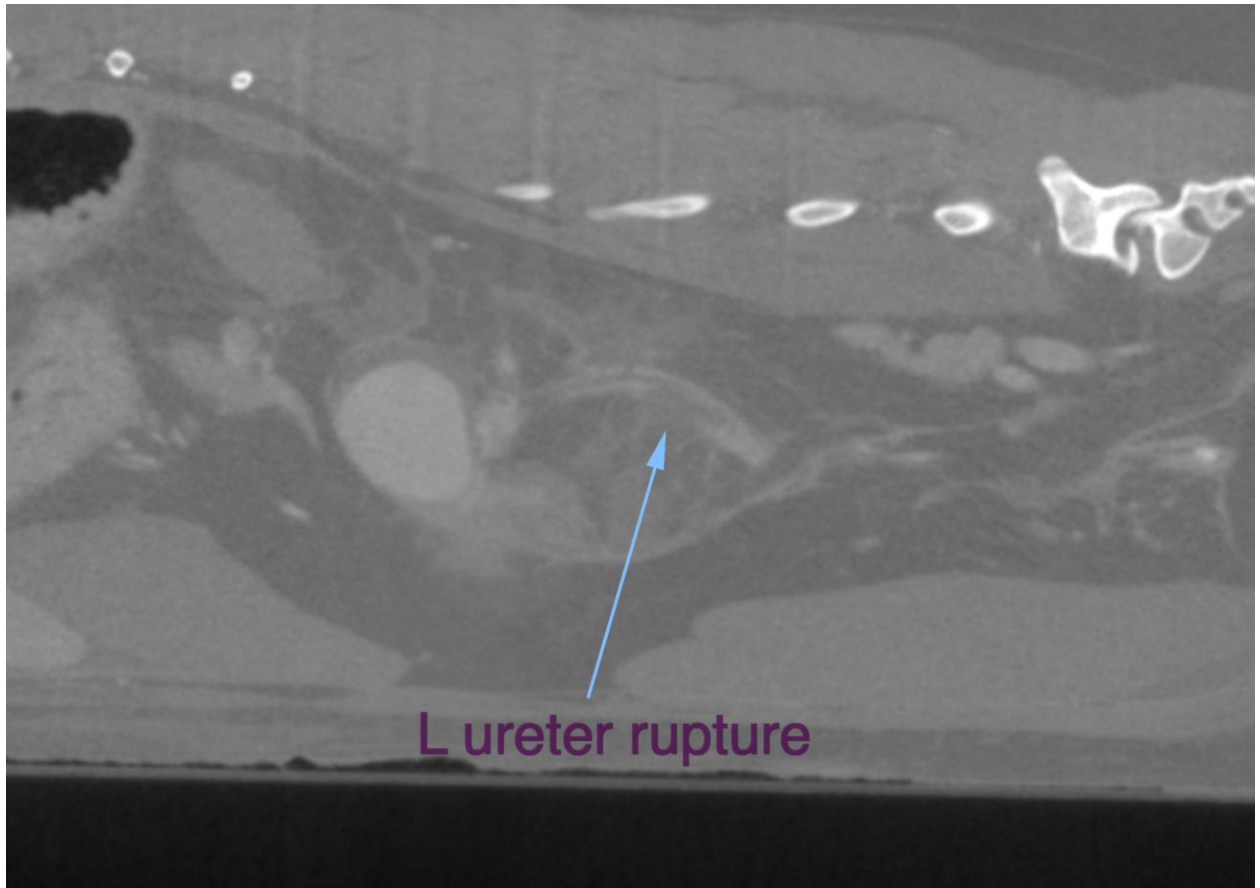
MN

AGE

5yr

INTERPRETED BY

Nele Eley (Ondreka),
DVM Dr. med. vet.,
DipECVDI



HOSPITAL NAME

Rockaway Animal
Hospital

REFERRING VET

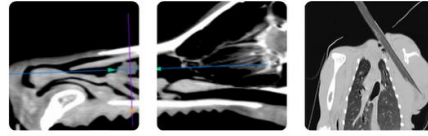
Dr Maniar

INVOICE

23789

DATE

02/04/2026



PATIENT

Fritzi Mitchko

The information and recommendations provided are based on the images presented by the referring veterinarian. No evaluation can be communicated regarding pathology that was not visible in the image/video clips provided.

SPECIES

Canine

Thank you for this referral. If the clinical or image interpretation does not parallel your findings or if I can be of any further assistance please contact me.

BREED

Miniature Schnauzer

Nele Eley (Ondreka), DVM, Dr. med. vet., DipECVDI
European Specialist in Veterinary Diagnostic Imaging, Cert. Radiology,
Senior lecturer University of Giessen/Germany, Veterinary Faculty, Department of Radiology.
info@sonopath.com

SEX

MN

AGE

5yr

INTERPRETED BY

Nele Eley (Ondreka),
DVM Dr. med. vet.,
DipECVDI

HOSPITAL NAME

Rockaway Animal
Hospital

REFERRING VET

Dr Maniar

INVOICE

23789

DATE

02/04/2026